

# Up-Slanting Palpebral Fissures and Oblique Astigmatism Associated With A-Pattern Strabismus and Overdepression in Adduction in Spina Bifida

Evelyn A. Paysse, MD,<sup>a,b</sup> Amjad Khokhar, MD,<sup>a</sup> Kathryn M. Brady McCreery, MD,<sup>a</sup> Michael C. Morris, MD,<sup>c</sup> and David K. Coats, MD<sup>a,b</sup>

**Purpose:** To describe the spectrum of adnexal and ophthalmologic features in spina bifida. **Methods:** A retrospective review of the medical records of 73 patients was conducted. Data concerning ocular motility, palpebral fissure orientation, presence and axis of astigmatism, visual acuity, amblyopia, and stereopsis were analyzed. **Results:** Forty-three (59%) of the 73 patients had strabismus: 28 (65%) had esotropia, 12 (28%) had exotropia, and 3 (7%) had orthotropia in primary gaze and a significant A-pattern. Of the strabismic patients, 20 (47%) had an A-pattern, of which 13 (65%) demonstrated overdepression in adduction. Twenty-seven (84%) of the 32 patients with documented palpebral fissure orientation had exaggerated up-slanting palpebral fissures. Forty-nine (77%) of 64 patients exhibited astigmatism greater than 0.75 D in at least 1 eye, with a mean power of 1.6 D. The axis of cylinder was oblique in 76% of these patients. The astigmatic axis was consistently oriented perpendicular to the eyelid fissure orientation in the group of patients with up-slanting palpebral fissures, with the mean axis of cylinder being incyclorotated (OD axis, 77; OS axis, 108). Up-slanting palpebral fissures were associated with a 15-fold increased chance that the axis of cylinder would be incyclorotated ( $P = .07$ , chi-square test). An orbital computed tomographic (CT) scan of a spina bifida patient with A-pattern esotropia, overdepression in adduction, and up-slanting palpebral fissures demonstrated significant incyclorotated extraocular muscle pulley heterotopy. **Conclusions:** Exaggerated up-slanting palpebral fissures are a prominent feature in spina bifida. Up-slanting palpebral fissures in spina bifida patients are associated with incyclorotated oblique astigmatism, A-pattern strabismus, and overdepression in adduction. These associations might be related to an anomaly of orbital skeletal or extraocular muscle pulley development. Further prospective study is encouraged. (J AAPOS 2002;6:354-9)

Spina bifida is the most common congenital anomaly of infants born in the United States.<sup>1</sup> It results from failure of fusion of the vertebral arches, which leaves the spinal cord unprotected posteriorly. Management of spina bifida has greatly improved over the last century. With the improved survival rate of spina bifida patients, medical specialists must now manage a host of medical

problems that were previously unrecognized. Neurosurgical, genitourinary, and orthopedic abnormalities of spina bifida have been well established, but data regarding ophthalmologic abnormalities in spina bifida patients are sparse. Only a few retrospective studies have examined the ophthalmologic findings in spina bifida patients.<sup>1,2-5</sup> Most of these earlier studies grouped spina bifida patients together with those having hydrocephalus from other etiologies, such as intraventricular hemorrhage, infection, tumor, or idiopathic causes. Spina bifida should be recognized as a distinct entity because its hydrocephalus results specifically from compression of the aqueduct of Sylvius due to an Arnold-Chiari malformation.

We have noted a characteristic adnexal finding in the spina bifida population at our institution, characterized by exaggerated up-slanting palpebral fissures (Figure 1). The purposes of this study were to report the characteristic adnexal finding, review ophthalmologic features in spina bifida, and propose a reason for the association between the palpebral fissure orientation and the other ophthalmologic features in this patient group.

From Cullen Eye Institute, Department of Ophthalmology,<sup>a</sup> Department of Pediatrics,<sup>b</sup> and Department of Radiology, Baylor College of Medicine, Texas Children's Hospital, Houston.<sup>c</sup>

This study was presented at the annual meeting of the American Association for Pediatric Ophthalmology and Strabismus, San Diego, California, April 13, 2000.

This study was supported in part by an unrestricted grant from Research to Prevent Blindness, Inc., New York, NY.

Submitted May 22, 2001.

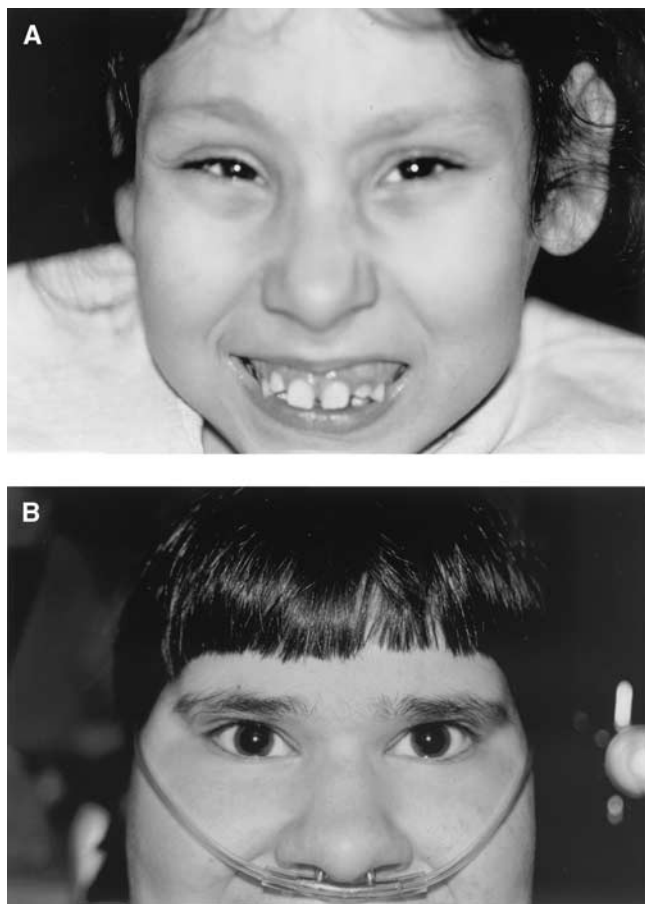
Revision accepted July 28, 2002.

Reprint requests: Evelyn A. Paysse, MD, Texas Children's Hospital, 6621 Fannin, MC CC640.00, Houston, TX 77030; e-mail, epaysse@bcm.tmc.edu

Copyright © 2002 by the American Association for Pediatric Ophthalmology and Strabismus.

1091-8531/2002/\$35.00 + 0 75/1/129042

doi:10.1067/mpa.2002.129042



**FIG 1. A and B,** Typical exaggerated up-slanting eyelid fissures of patients with spina bifida. Note that lateral canthus is much higher than medial canthus.

## METHODS

A search of the pediatric ophthalmology computer database at our institution was performed to identify patients with a diagnosis of spina bifida over a 14-year period. The medical records of 82 patients with spina bifida were retrievable, but 9 were excluded because comprehensive ophthalmology records were unavailable. The medical records of 73 patients were retrospectively reviewed with attention to demographics, vertebral level and type of spinal defect, presence or absence of hydrocephalus, ocular alignment at distance and near, ductions and versions for comitance, overelevation and overdepression in adduction, palpebral fissure orientation, presence and axis of astigmatism, best-corrected visual acuity, amblyopia, stereopsis, anterior segment examination, fundus examination, and orbital computed tomographic (CT) scan findings.

Ocular alignment was routinely measured, according to the standard in our clinic, with the most sophisticated method of testing possible based on patient cooperation, which was usually alternate prism and cover test. For less cooperative patients, Krinsky measurements were made. For pattern strabismus detection, the distance upgaze alignment was measured at approximately 25° above the

midline, and distance downgaze alignment was measured at approximately 25° to 35° below the midline. An A-pattern esotropia was defined as an esotropia at least 10 PD worse in upgaze than in downgaze. An A-pattern exotropia was defined as an exotropia at least 10 PD worse in downgaze than in upgaze. A V-pattern esotropia was defined as an esotropia at least 15 PD worse in downgaze than in upgaze. A V-pattern exotropia was defined as an exotropia at least 15 PD worse in upgaze than in downgaze.

Overelevation and overdepression in adduction (often referred to as inferior oblique or superior oblique overaction, respectively) were graded by faculty pediatric ophthalmologists (E.A.P., D.K.C.) on a scale from -4 to +4, with 0 equaling normal function, -4 equaling severe underaction, and +4 equaling severe overaction. More specifically, with the abducting eye fixing, if the eye in direct adduction was noted to be hypertropic relative to the fixating eye, at least +3 overelevation in adduction was present, and if the eye in adduction was noted to be hypotropic relative to the other eye, at least +3 overdepression in adduction was present. Further breakdown was made from this reference point.

Documentation of palpebral fissure orientation was subjective, based on the faculty ophthalmologist's impression of horizontal, up-slanting, and down-slanting eyelid fissures. The description of slant related to the lateral canthus relative to the medial canthus. The normal eyelid typically has a lateral canthus that is approximately 1 mm higher than the medial canthus. Up-slanting fissures were noted typically if the lateral canthus was higher than the medial canthus by more than about 1 mm. No more sophisticated method of evaluating eyelid fissures was performed because this was a retrospective study. Additionally, because this was a retrospective study and palpebral fissure orientation is generally not considered a physical abnormality, this observation was not always noted and available.

Refractive error was measured by streak retinoscopy in all patients after cycloplegia with 1% cyclopentolate and 2.5% phenylephrine. Darkly pigmented eyes routinely received the dilating drops in both eyes every 5 minutes for 2 or 3 sets. Blue eyes routinely received 1 set of both medications in both eyes. Cycloplegic refractions were carried out approximately 45 minutes after the drops were instilled. Astigmatism was defined as cylinder greater than 0.75 D.

Visual acuity was measured with the most sophisticated test possible for each child. Amblyopia was defined in verbal children as a best-corrected visual acuity in the affected eye that was worse than that of the fellow eye by 2 lines or more on the visual acuity chart. If a child was preverbal or nonverbal, amblyopia was diagnosed if a fixation preference for 1 eye was encountered. Evaluation of fixation preference was performed with the cover test in strabismic patients or the 10-D vertical prism test in or-

thotropic patients.<sup>6</sup> Stereopsis was measured with the Titmus stereo fly test.

An orbital CT scan of a spina bifida study patient with A-pattern esotropia, overaction in adduction, and up-slanting palpebral fissures was compared with orbit scans of 4 normal age-matched nonstrabismic children. On the coronal view, a line was drawn across the eye on the horizontal (180°). Another line was drawn connecting the lower edge of the lateral rectus pulley to the lower edge of the medial rectus pulley. The angle created by the 2 lines was determined and compared. This comparison was done at the level of the equator of the globe, 3 mm posterior to the equator and 9 mm posterior to the equator.

Statistical analysis was done with the  $\chi^2$  test.

## RESULTS

### Demographics, Type of Spina Bifida, and Hydrocephalus Status

Seventy-three patients with spina bifida were included; 35 (47%) were male. The mean age was 5.8 years (2 months to 21 years). Forty-five (62%) were Hispanic, 16 (22%) were white, 11 (15%) were black, and 1 (1%) was of Middle Eastern descent. Sixty-three (86%) patients had meningocele, 4 (5%) had meningocele, 1 (1%) had spina bifida occulta, and 5 (7%) had no mention of the level of the spina bifida. Sixty-eight (93%) patients had a known history of hydrocephalus.

### Ocular Alignment and Versions

Forty-three (59%) of the 73 subjects had strabismus. Of the 43 patients with strabismus, 28 (65%) had esotropia, 12 (28%) had exotropia, and 3 (7%) had orthotropia in the primary position with an A-pattern. Eighteen (64%) of the 28 esotropic patients had early onset large-angle esotropia, defined as onset before 1 year of age. Five (18%) had accommodative esotropia, and 4 (14%) had abducens palsy. The most prevalent exodeviation was basic exotropia, present in 7 (58%) of the 12 exotropic patients (Table 1).

Twenty (47%) of the 43 patients with strabismus had an A-pattern; 65% of these exhibited overdepression in adduction with a mean overaction of +1.7. Six (14%) of the 43 strabismic subjects had a V-pattern, with an equal distribution of esotropia and exotropia. Inferior oblique overaction was found in 67% of these patients, with a mean overaction of +1.7.

### Palpebral Fissure Orientation, Presence of Astigmatism, and Axis of Astigmatism

Thirty-two (44%) of the 73 patients had documentation of palpebral fissure orientation. Twenty-seven (84%) had up-slanting palpebral fissures, 4 (13%) had horizontal fissures, and 1 (3%) had down-slanting fissures (Figure 2). Sixty-four (88%) of the 73 patients underwent cycloplegic refraction. Forty-nine (77%) of these 64 patients exhibited

**TABLE 1.** Ocular alignment in total spina bifida cohort (73 patients)

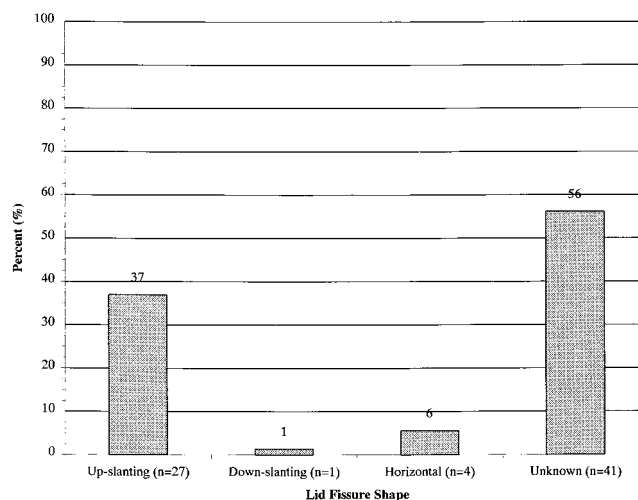
Deviation	Type	n	% of total
Orthotropia	Total	33	45
	No pattern	30	41
	A-pattern strabismus	3†	4
Esotropia	Total	28	38
	Early onset*	18	25
	Late onset	1	1
	Accommodative	5	7
	VI cranial nerve palsy	4	5
Exotropia	Total	12	16
	Basic	7	10
	Convergence insufficiency	2	3
	Divergence excess	2	3
	Sensory	1	1

\*Early-onset esotropia, esotropia with onset before 1 year of age.

†Three patients who were orthotropic in primary gaze group had A-pattern; they were included in strabismus group.

astigmatism of at least 0.75 D in at least 1 eye, with a mean power of cylinder of 1.6 D. Twenty-two (84%) of the 27 patients with noted up-slanting palpebral fissures had a documented refraction, and 16 (73%) had astigmatism of at least 0.75 D. None of the patients with horizontal or down-slanting palpebral fissures had astigmatism of more than 0.75 D.

When the patients with palpebral fissure documentation and astigmatism were subdivided by palpebral fissure orientation, the astigmatic axis fell into consistent patterns in which the axis was oriented perpendicular to the eyelid fissure. In the group with up-slanting palpebral fissures and astigmatism, the axis of positive cylinder tended to be incyclorotated (ie, axis of cylinder in the right eye between 0° and 90°, and axis of cylinder in the left eye between 90° and 180°). The mean axis of positive cylinder was 77° in the right eye and 108° in the left eye (Table 2). In the group with horizontal eyelid fissures, the mean axis of



**FIG 2.** Orientation of palpebral fissures.

**TABLE 2.** Eyelid fissure orientation and refractive error in patients who had palpebral fissure notation and astigmatism

Mean cycloplegic refraction	Eyelid fissure orientation*		
	Up-slanting (n = 22)	Horizontal (n = 3)	Down-slanting (n = 1)
OD spheroequivalent (D)	+1.11	-0.42	+1.00
OD cylinder (D)	+1.88	+0.75	+0.50
OD axis (°)	77	88	125
OS spheroequivalent (D)	+1.22	+0.25	+0.63
OS cylinder (D)	+2.03	+1.25	+0.25
OS axis (D)	108	88	110

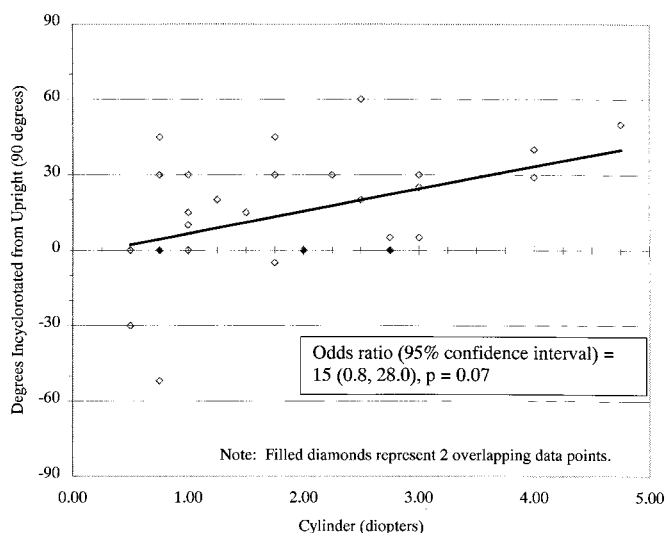
\*Eyelid fissure orientation was noted in 32 (44%) of the 73 patients included in the study cohort. OD, right eye; OS, left eye.

cylinder in both eyes was 88°, demonstrating standard “with-the-rule” astigmatism (Table 2).

To evaluate trends more easily in the group with up-slanting palpebral fissures and astigmatism (16 patients, 31 eyes), we converted left and right eye cylinder axes so that, in all eyes, 0° to 90° corresponded to an incyclorotated axis, and -90° to 0° corresponded to excyclorotated axis of cylinder (Figure 3). Statistically, up-slanting palpebral fissures in our spina bifida population were associated with a 15-fold increased chance that the axis of cylinder would be incyclorotated ( $P = .07$ , chi-square test).

### Visual Acuity, Amblyopia, and Stereopsis

Forty-five (62%) of the 73 patients could perform quantitative psychophysical visual acuity testing, and 27 (37%) had only their visual behavior assessed because of poor comprehension or young age. The geometric mean visual acuity in the better eye was 20/26 (0.14 logMAR) (range, 20/15-20/70). Forty-two (93%) of the 45 subjects with quantitative visual acuity had a visual acuity of 20/40 (0.30 logMAR) or better in the better-seeing eye.



**FIG 3.** Astigmatism plotted against incyclorotated axis of cylinder for both eyes of all patients with astigmatism and up-slanting palpebral fissures. Positive degree values on Y-axis correlate with incyclorotated axis, and negative degree values correlate with excyclorotated axis. Almost all eyes had incyclorotated axes of cylinder.

Amblyopia was diagnosed on at least 1 examination in 15 (21%) of the 73 patients. The amblyopia was due to strabismus in 12 (80%) patients, anisometropia in 2 (13%), and both strabismus and anisometropia in 1 (7%).

Stereopsis data were available for 26 (36%) subjects (mean age, 9.6 years) who cooperated for testing. The level of stereopsis was reduced to 100 seconds of arc or less in 18 (69%) patients.

### Anterior Segment and Fundus Findings

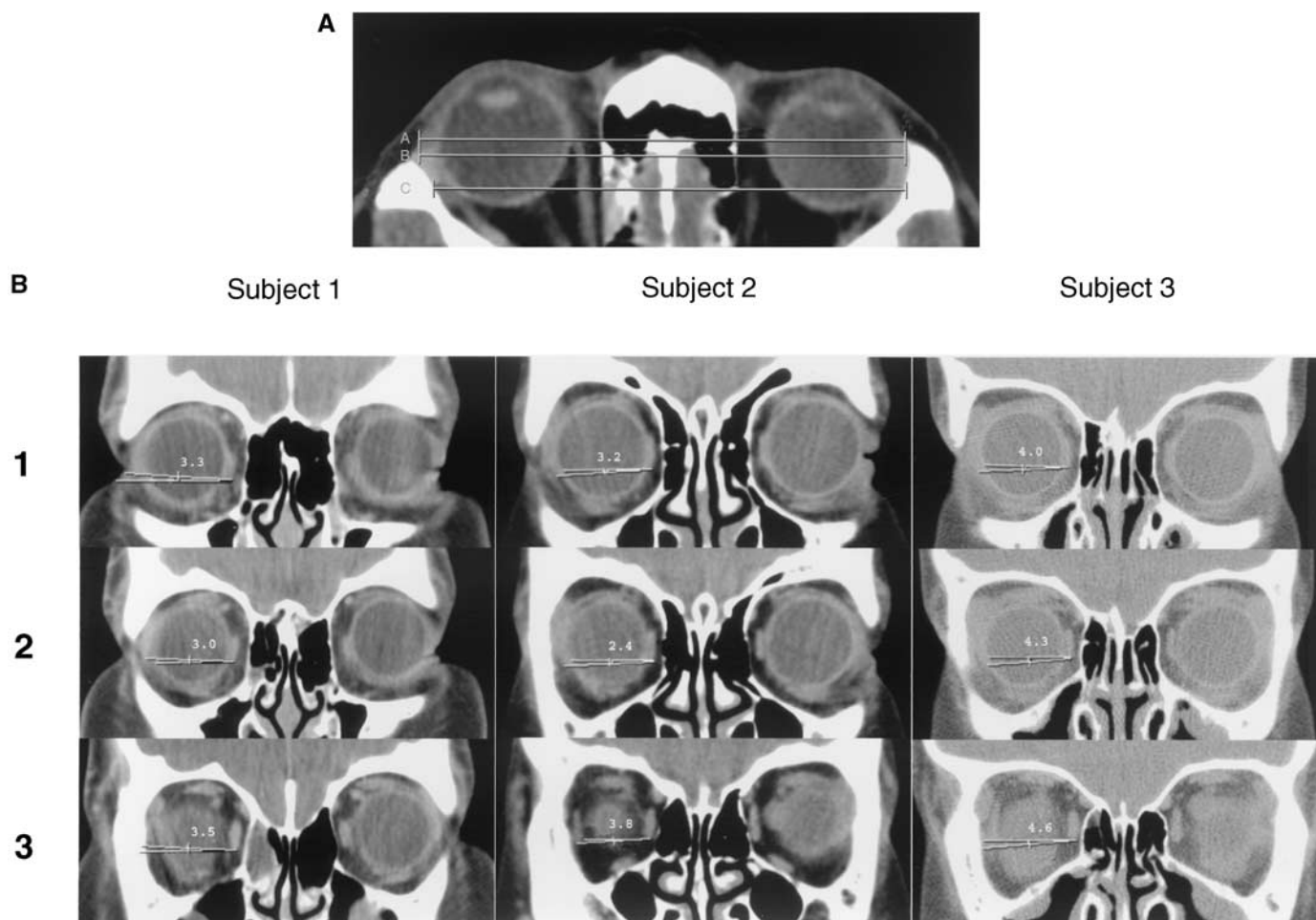
All patients had normal anterior segments. Two (3%) of the 68 patients with documented fundus examinations had optic atrophy. One subject who had up-slanting palpebral fissures, A-pattern esotropia, and overdepression in adduction was noted to have bilateral fundus incyclotropia.

### Orbital CT Scan Findings

One preoperative orbital CT scan was available of a study patient with spina bifida and significant strabismus. This patient had A-pattern esotropia, overdepression in adduction, and up-slanting palpebral fissures. The CT scan showed significant extraocular muscle pulley heterotopy in an incyclorotated direction. The lateral rectus muscle pulleys were incyclorotated a mean of 3.3° from the horizontal meridian in comparison with 2 normal age-matched, nonstrabismic patients in whom the lateral rectus pulleys were excyclorotated a mean of 3.4° from the horizontal meridian (Figure 4). This finding was consistent in 2 other scans of normal nonstrabismic patients that we reviewed.

### DISCUSSION

This study has an important weakness that must be acknowledged. Because it was retrospective, there is the ever-present problem of the “disappearing denominator.” That is, there are missing data points in each section of analysis that could lead to biases and misinterpretations. This problem, albeit important, is shared by all retrospective studies. But even with this weakness, important information and potential associations can be discovered from retrospective data. This information in turn supports the need for further prospective investigation. We believe that our study, despite its weakness, demonstrates an important association of 4 physical findings in spina bifida patients



**FIG 4.** Orbital CT scan of spina bifida patient with A-pattern esotropia, overdepression in adduction, and upslanting palpebral fissures (subject 1) compared with 2 normal, age-matched nonstrabismic patients (subjects 2 and 3). **A**, Axial scan demonstrating where the following coronal images are taken; **B**, image 1 is at level of equator of globe, image 2 is 3 mm posterior to equator, and image 3 is 9 mm posterior to equator. Lateral rectus pulley is higher than medial rectus pulley in spina bifida patient and lower than medial rectus pulley in normal, age-matched nonstrabismic subjects.

that might relate to a global anatomic variant in this population.

Several unique adnexal and ophthalmologic features were identified in our spina bifida patients. We found a 59% prevalence of strabismus in those attending our ophthalmology clinic compared with a 2% to 5% prevalence of strabismus in the general population.<sup>4</sup> This rate is similar to that reported by Biglan,<sup>2</sup> who found a prevalence of 61%, but is higher than the 34% prevalence reported by Rothstein et al.<sup>7</sup>

In our cohort of patients with strabismus, esotropia was more commonly encountered than exotropia; this agrees with previous studies.<sup>2-4,7,8</sup> Two previous studies suggested that the high prevalence of esotropia in spina bifida patients was due to abducens nerve palsy after recurrent episodes of increased intracranial pressure and hydrocephalus.<sup>3,8</sup> Abducens palsy, however, was present in only 14% of our esotropic patients. Early onset large-angle esotropia unrelated to abducens paresis was the predominant characterization of our patients.

A-pattern strabismus has been frequently reported in patients with spina bifida.<sup>2,3,5</sup> We, too, found a high prevalence of A-pattern strabismus, present in 47% of our strabismic patients. Although the cause of A-pattern strabismus in spina bifida is debated, the pattern is commonly associated with overdepression in adduction and hydrocephalus.<sup>9</sup> Sixty-five percent of our patients with an A-pattern exhibited overdepression in adduction. Gaston<sup>3</sup> speculated that A-pattern strabismus was due to either a high prevalence of lateral rectus paresis or a downdrift in adduction because of weakness of the inferior oblique muscles. Biglan<sup>5</sup> hypothesized that A-pattern strabismus in spina bifida might result from a vertical gaze pathway disruption secondary to a midbrain defect, characterized by dorsal midbrain "beaking." Hamed et al<sup>10</sup> suggested that the Arnold-Chiari II malformation often present in spina bifida could cause the A-pattern strabismus with overdepression in adduction by compressing the cervicomedullary junction, producing an alternating skew deviation in lateral gaze. We propose another possible ex-

planation for this pattern strabismus, to be discussed shortly.

In addition to strabismus, oblique astigmatism was frequently present in our patient group; this agrees with Biglan's findings.<sup>2</sup> We also found a high prevalence of up-slanting palpebral fissures, a finding that has not yet been reported. Most interestingly, however, was the observation that the astigmatic axis in our patient group was almost always oriented perpendicular to the eyelid fissure (Figure 3, Table 2). The normal axis of cylinder in children is at approximately 90° ("with the rule"), and normal eyelid orientation is horizontal. In our study group, the eyes of spina bifida patients with up-slanted palpebral fissures usually had an incyclorotated axis of cylinder. There were too few patients with horizontal or downslanting fissures to make any definite conclusion regarding cylinder orientation in these groups.

We propose that the 4 findings in our spina bifida cohort—A-pattern strabismus, overdepression in adduction, up-slanting palpebral fissures, and incyclorotated axis of cylinder—might all be due to an orbital developmental abnormality, characterized by incyclorotation of the orbits with resultant heterotopy of the extraocular muscle pulleys. Clark et al<sup>11-13</sup> described the presence of heterotopic extraocular muscle pulleys in other pattern strabismus entities, proposing that this pulley heterotopy causes the strabismus. Indeed, we have shown, in an orbital CT scan of a spina bifida patient with these findings, significant extraocular muscle pulley heterotopy in the incyclorotated direction. Fundus incyclotropia, a finding for which we do not routinely evaluate, was also noted in another patient in our group.

We believe that extraocular muscle pulley heterotopy partially explains these findings in spina bifida. If the medial rectus pulley is located too low and the lateral rectus pulley is located too high in the orbit, the eye would be incyclorotated. The resultant movement of the eye when the medial rectus contracted would be overdepression in adduction. An A-pattern would be present because the inferior rectus pulley would be located more laterally, causing an abducting vector in addition to depression. Because the eye would be in an incyclorotated position, the axis of cylinder would also tend to be rotated in this same direction.

Heterotopic pulleys, however, do not explain the exaggerated up-slanted palpebral fissures we encountered in this group. We believe that this eyelid fissure orientation might be a result of orbital skeletal incyclorotation and that this skeletal rotation leads to the pulley heterotopy. A similar but opposite orbital excyclorotation has been sug-

gested in patients with craniosynostosis who have the opposite eye findings of down-slanting palpebral fissures and overelevation in adduction.<sup>14</sup> Normative CT data of orbital bones do not now exist so that this possibility can be further evaluated.

## CONCLUSIONS

We confirmed a high prevalence of A-pattern strabismus with overdepression in adduction in patients with spina bifida. We also identified an association of exaggerated up-slanting palpebral fissures and oblique astigmatism oriented perpendicular to the palpebral fissure in spina bifida patients attending our clinic. These findings might be related to an anomaly of orbital skeletal development and extraocular muscle pulley heterotopy. Prospective studies are needed to further investigate these possibilities.

## References

1. Sarwark JF. Spina bifida. *Pediatr Clin North Am* 1996;43:1151-8.
2. Biglan AW. Ophthalmologic complications of meningocele: a longitudinal study. *Trans Am Ophthalmol Soc* 1990;88:389-462.
3. Gaston H. Ophthalmic complications of spina bifida and hydrocephalus. *Eye* 1991;5:279-90.
4. National Society to Prevent Blindness: Vision Problems in the US.: Data analysis, definitions, data sources, detailed data table, analysis, interpretation. Schaumburg (Ill): 1980.
5. Biglan AW. Strabismus associated with meningocele. *J Pediatr Ophthalmol Strabismus* 1995;32:309-14.
6. Wright KW, Walonker F, Edelman P. 10-diopter fixation test for amblyopia. *Arch Ophthalmol* 1981;99:1242-6.
7. Rothstein TB, Romano PE, Shoch D. Meningocele. *Am J Ophthalmol* 1974;77:690-3.
8. Clements DB, Kaushal K. A study of the ocular complications of hydrocephalus and meningocele. *Trans Ophthalmol Soc UK* 1970;90:383-90.
9. France TD. The association of A-pattern strabismus with hydrocephalus. In: Moore S, Mein J, Stockbridge L, editors. *Orthoptics: past, present, and future*. New York: Grune & Stratton; 1976. p. 287-92.
10. Hamed LM, Maria BL, Quisling RG, Michele JP. Alternating skew on lateral gaze: neuroanatomic pathway and relationship to superior oblique dysfunction. *Ophthalmology* 1993;100:281-6.
11. Clark RA, Miller JM, Demer JL. Location and stability of rectus muscle pulleys: muscle paths as a function of gaze. *Invest Ophthalmol Vis Sci* 1997;38:227-40.
12. Clark RA, Miller JM, Demer JL. Displacement of the medial rectus pulley in superior oblique palsy. *Invest Ophthalmol Vis Sci* 1998;39:207-12.
13. Clark RA, Miller JM, Rosenbaum AL, Demer JL. Heterotopic muscle pulleys or oblique muscle dysfunction? *J AAPOS* 1998;2:17-25.
14. Limon de Brown E. Strabismus in Crouzon's disease. *Transactions of the International Strabismological Association, 2nd Congress, Marseilles, France*. Paris: Diffusion Generale De Librairie; 1974. p. 371-85.